



Microbial Science Archives (ISSN: 2583-1666)

Journal homepage: www.microbial.sciencearchives.org



<https://doi.org/10.47587/MSA.2022.2401>



Research Article

Spread of *Trichomonas gallinae* in species of birds in balad district with the effect of infection on histological picture

Ban Najem Abdulla¹ Ashraf Jamal Mahmoud Zangana¹✉ and Ayser Salih Mohamed²

¹Biology Department, College of Education for Women, Tikrit University, Iraq

²Biology department, College of Education, Samara University, Iraq

Received: Sept 27, 2022/ Revised: Oct 20, 2022/ Accepted: Oct 24, 2022

(✉) Corresponding Author: dr.ashraf_bio@tu.edu.iq

Abstract

Trichomoniasis in birds is one of the most common types of infection that affects birds worldwide, and it is caused by *Trichomonas gallinae*. This study was carried out to examine and determine the presence of *T. gallinae* in *Columba livia*, *Streptopelia turtur*, and *Gallus gallus domesticus* microscopic examination (direct smear and Giemsa stained). The study was conducted in Balad district in Salah al-Din Governorate, north of Baghdad, Iraq, from October 2021 to March 2022. The results showed the microscopic examination that the incidence of *T. gallinae* average was 19.17%, distributed between 14.16% for *C. livia*, while *S. turtur* constituted 14.0%, and the rate of *G. gallus domesticus* was 27.92%, but there were no significant differences at $P > 0.05$ among these bird species. The gender of birds showed that there were no differences between a male and a female of each type. In males of the two types of pigeons (*C. livia*, and *S. turtur*) and *Gallus gallus domesticus*, the rates of infection were (16.10, 15.05, and 5.75 %), while in female types of *C. livia*, *S. turtur*, and *Gallus gallus domesticus*, the rates of infection were (12.17, 12.28, and 31.11%), respectively. The incidence of *T. gallinae* is distributed for the most studied months, as it showed the highest infection rate for pigeons in January at 20% for *C. livia*, and 32% for *S. turtur*, and while January to February had 33% as the highest rate of infection in *G. gallus domesticus*, although there were no significant differences ($P > 0.05$) among studied birds. The histological changes of infected organs for all species as well as for healthy birds, as the parasite was located in the upper part of the gastrointestinal tract, which was tongue, pharynx, vesicle, and gizzard. Granular lesions and infiltration of lymphoid and inflammatory cells were found, as well as degeneration in a number of gland-forming cells. The mucous in the affected areas as a result of parasite penetration into the tissue, congestion of blood vessels and appearance of granulation tissue in the upper part of healthy alimentary canal was compared with that of *C. livia*, *S. turtur* and *Gallus gallus domesticus* of Balad district. In pharynx, the infiltration of large numbers of white blood cells, scattered and nodular form, and the sloughing of surface cells, and presence of strands of sloughed keratin appeared in pharynx cavity, and in vesicle tissue, and in gizzard, the histological sections showed the presence of parasite in muscle layer surrounded by a white transparent band, the infiltration of a large number of white blood cells appeared, and degeneration of epithelial cells at the bases of epithelial cells appeared in mucous folds.

Keywords *Trichomonas gallinae*, *Columba livia*, *Streptopelia turtur*, *Gallus gallus domesticus*, histopathological effects.

Introduction

Livestock constitutes an important aspect in the agricultural sector, as it is no less important than the vegetable aspect as it is a basic source of food and a source of animal protein that is

easily digestible to humans, as the proportion of protein in livestock and poultry meat reaches 20%, while the proportion of protein in fruits 0.7%, vegetables, 0.1%, and most animal products are raw materials used in the industrial sector, Natural animals are affected by a wide range of large parasites

(such as helminths and arthropods), and micro-pathogens (such as bacteria, viruses, protozoa and fungi) (Alrefaei et al., 2019).

Pigeons are the fourth largest producer of poultry and there are nearly four million pairs of pigeons raised in our country. Pigeon meat is consumed as a kind of nutritious food, and pigeon meat is used as a source of nutrition and is supported by consumers (Ji et al., 2020a). It is the main host of the parasite *T. gallinae* and is transmitted between birds through shared water sources (Purple et al., 2015).

The ulceration is caused by *T. gallinae*, causing heavy losses and high numbers of birds. The main host of *T. gallinae* is the rock pigeon *Columba livia*, which is believed to be responsible for the spread of primary infection worldwide (Ji et al., 2020 a). The pathogenic parasite *Trichomonas gallinae* infects the mouth, including the tongue, pharynx, esophagus, and gizzard of domestic pigeons, wild birds and birds of prey. Direct swab of material scraped from the oral cavity of infected birds or culture of this material in a suitable growth medium followed by examination can be used to diagnose the parasite (Cover et al., 1994). Trichomoniasis is an acute and generally fatal disease that presents as a cheesy lesion within the upper gastrointestinal tract of infected birds (Brunthaler et al., 2022). The disease causes clinical signs in infected birds represented by weakness and emaciation of infected pigeons, difficulty in breathing and swallowing water and food, drooling of saliva, and in some cases diarrhea is noted.; 1994).

A study was conducted in Baghdad city on 168 domestic pigeons of *Columba livia domestica*, and the results showed that 58.33% of the tested pigeons were positive for *T. gallinae* infection, the infection rate among the examined pigeons was 65.45%, 62.29% and 46.15% in adult females, males and chicks on the respectively, seasonally, and the highest incidence was 64.1% in spring, 62.4% in winter and 61.2% in summer. While the lowest infection rate was recorded in the fall, 43.2% (Jaafar, 2014). A study was conducted in the Kurdistan region on 249 birds, 142 pigeons and 107 domestic pigeons. The infection rate of Columbides *T. gallinae* was 20.42% in pigeons and 23.36% in domestic pigeons. (Wahhab et al., 2017)

In Baghdad city, the results were 58% for adult wild pigeons and 66% for immature wild pigeons out of a total of 180 adult and 126 non-adult pigeons, respectively (Fadhil & Faraj, 2019). The results were 10.3% of the ornamental pigeons were infected and 12.6 of the broiler pigeons were infected with the same disease (Jawad et al., 2020)). In the year 2022, a study was conducted in the Muthanna Governorate on both domestic and wild pigeons, and the percentage of domestic pigeons was 20.25% and wild pigeons were 26 % (Dakheel et al., 2022).

The study aimed to investigate the infection of three types of birds (*Columba livia*, *Streptopelia turtur*, *Gallus gallus domesticus*) with *Trichomona gallinae* in Balad district, and to determine the infection rate of the parasite for each type of bird under study with knowing the effect of the parasite on the histological picture.

Materials and methods

Sampling area

605 samples belonging to three types of Iraqi birds were examined for the period between 1/10/2022 - 1/4/2022 from different areas in Balad District, north of Baghdad within Salah al-Din Governorate. On the traditional methods followed by pigeon breeders and confirming this by identifying the male and female reproductive organs after killing the birds by slaughtering and dissecting them.

Laboratory tests

A- Clinical and gross examination of samples

A preliminary examination was conducted on all the birds under study to ensure their apparent safety from disease pests of other diseases, while clinical signs were recorded and the presence of macroscopic lesions associated with trichomoniasis were recorded, and the macroscopic examination included the oral cavity, pharynx and the entrance to the respiratory tract. A questionnaire was organized with information about birds

B - Microscopic examination of the models

Wet cotton swabs were taken directly from the wall of the oral cavity, pharynx and esophagus. The swabs were mixed with a drop of physiological saline by carefully rolling the cotton end of the swab over the surface of a slide and covering it with a sterile slide cover. Then it was examined under a light microscope with a magnification of X 40 and X 100. The shape of the parasite and its characteristic vibrational movement were observed by The anterior flagella and the undulating membrane (Abdle-Motelib and Galal, 1993).

B- Giemsa stain

5 drops of komsa tincture, at a concentration of 10%, were placed on the glass slide on which the swabs were fixed for 30 minutes, after which the slide was washed with distilled water, then placed in a mantle to dry at room temperature. Parsani).

C- Preparation of tissue sections

Histological sections were prepared after autopsying the birds under study and taking certain organs (tongue, pharynx and esophagus) from healthy and infected birds according to the method (Bancroft & Gamble, 2008).

Results and Discussions

602 birds were examined distributed among 233 Turanian blue pigeons, 222 domesticated chickens, and 150 lunar pigeons as shown in Table (1). The macroscopic examination of all study birds revealed that 116 birds were positive for trichomoniasis, of which 33 were *C. livia* with a ratio of 14.16 %, 62 of *G. gallus* with a percentage of 27.92 % and finally 21 of the lunar pigeons with a percentage of 14.0%. Significant differences

were recorded between *C. livia* and *S. turtur* with *G. gallus*, where the largest percentage of *G. gallus* was and no significant differences were recorded between the two types of pigeons $P > 0.05$ (Table 1).

The results agreed with a study conducted in the Kurdistan region, which gave a close percentage of 21.69% positive for trichomoniasis in the examined domestic pigeons (Wahhab et al., 2017) and with a study in Muthanna Governorate on both domestic and wild pigeons, and the percentage of domestic pigeons was 20.25% and wild pigeons by 26% (Dakheel et al., 2022) and did not agree with (Jawad et al., 2020) in Karbala, where it recorded low infection rates of 10.3% for ornamental pigeons and 12.6 for broiler pigeons.

The differences in the rates of infection may be due to several reasons, including the nature of the climate, geographical differences, seasonal changes, host resistance, different birds in feeding habits, age of birds, numbers of birds examined in the study, breeding and living conditions of birds, and their participation in the stress factor, as well as the overcrowding of the feeding unit. That some types of pigeons do not have resistance to the disease strain, and the method of raising domestic pigeons in a small tower facilitates the transmission of the parasite between birds (Salem et al., 2008).

Table (2) shows the infection rate of each of the *C. livia*, *S. turtur* and *G. gallus*. The *C. livia* males showed 19 infected birds out of a total of 118 birds, with an infection rate of 16.10%, while the females showed an injury of 14 birds out of a total of 115 birds, with an infection rate of 12.17% and no differences. Significant. It was also found that 34 chickens out of a total of 132 male birds were infected with an infection rate of 25.75%, and 28 female chickens out of a total of 90 birds were infected with an infection rate of 31.11% and no significant differences, in addition to that, it was found that male *S. turtur* were infected with a rate of 15.05%, where the number of infected males was 14 birds out of a total of 93 birds, while the number of infected females was 7 birds out of a total of 57 birds with a rate of 12.28% and without significant differences. The results showed that there were no significant differences between males and females of the two types of pigeons, but significant differences were found between male and female *G. gallus* with the two types of pigeons $P > 0.05$.

The results of our study indicate an increase in the incidence of infection in males than in females by a very simple percentage, in all types of study birds, with no significant differences ($p > 0.05$) between the sexes, and this means that both sexes share an equal chance of infection, as these results agreed with (2011). (Al-Sadi & Hamodi, 2011)), where he indicated that male pigeons were infected with a higher percentage than females, and in Iraqi Kurdistan (2017) Wahhab mentioned that there were no significant differences in infection between males and females, and the current study differed with Al-Barwari and Saeed (2012), where he indicated an increase in the number of females in rock pigeons compared to males, and the higher rates of infection in males

than in females cannot be explained exactly, but it is assumed that it occurs due to female sex hormones that make the individual more susceptible to any infection (Alexander and Stimson, 1988 This may be attributed to the female's attachment to eggs, incubation and care of chicks, and her adoption of a limited food source, which weakens the immune system (Shubr, 2006).

Table (3) shows the percentage of infection with the parasite distributed according to the months of the study, where the highest percentage of infection of *C. livia* was recorded in January and it was 20%, where the number of infected birds was 9 birds out of a total of 43 birds, and the lowest percentage of infection was in October and it was 1 %, with the lowest number of infected birds 3 birds out of a total of 30 birds, as for *S. turtur*, the highest rate of infection was recorded in January as well, with a percentage of 32%, with 8 infected birds out of a total of 25 birds, and the lowest rate of infection was in February 1%, and it was 1%. The number of infected birds was 3 out of a total of 30. As for *G. gallus*, the highest infection rate was equal between January and February, with 14 and 11 birds out of a total of 42 and 33 birds, respectively, and the lowest infection rate was in November with 9 infected birds out of a total of 43 birds, and the statistical analysis between There were no significant differences between the three birds in the highest percentage, but the lowest percentage of infection, significant differences were found between the two types of pigeons and domesticated chickens at the probability level $P > 0.05$.

It was noted that the infection in birds begins in the fall and gradually rises until it reaches its peak in the middle of the winter, then decreases at the end of the season and then gradually decreases. This came in agreement with the (2007) McKeon and his group, as well as Bunby (2007) and his group, and the rise during the summer is attributed to a decrease in temperature and an increase in relative humidity in winter more than the seasons of the year, which is one of the conditions suitable for the growth, reproduction and spread of the parasite, as the parasite cannot live for a long time outside the body At high temperatures and because it also cannot encystment (because the vegetative phase is more sensitive to drought (Begum et al., 2008).

The results of the study showed the presence of gross and microscopic pathological changes in the organs of the affected birds that showed clinical signs characterized by general weakness, poor appetite, loss of weight, or suffering from emaciation due to the presence of caseous lesions in the mouth area with which it is difficult to swallow, difficulty breathing, closing eyes, and opening The beak, which is due to the inability of the bird to swallow food and the loss of sight in most of them.

It was observed in the infected turgor that the mucous tongue folds contained necrosis of the epithelium of some paper folds and the dispersal of their cells with the disintegration of the pulp of those folds. Necrosis was also found in the pulp of other folds. Muscle fibers Figure (1).

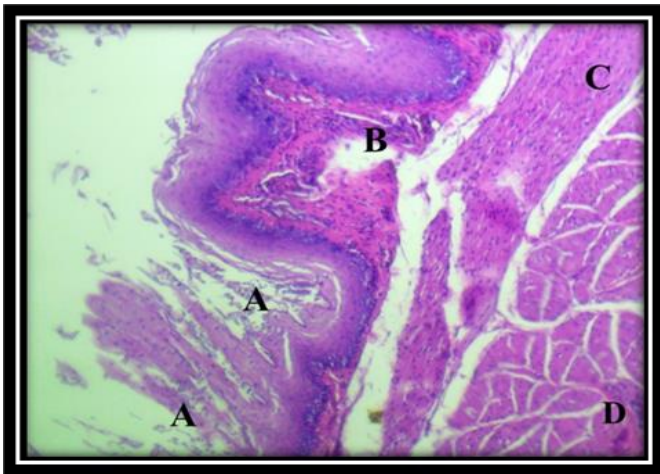


Fig. 1. Necrosis of the lingual folds and dispersal of its epithelial cells (A) Necrosis of the pulp of the folds (B) The inner circular muscle layer (C) The outer longitudinal muscle layer (D). (H&E, 400X)

The pharynx in *C. livia* also contained mucous pharyngeal glands with columnar cells secreting mucus containing a pale pigment and the nuclei of its basal-site cells of dark blue color and the bases of some of those glands with infiltration of a number of inflammatory white blood cells, and those glands of the type of histological tubular extending to the surface. The pharynx and around the glands were found a dense fibrous tissue in which a number of fibroblasts and from the outside a smooth muscular layer surrounded by Figure (2).

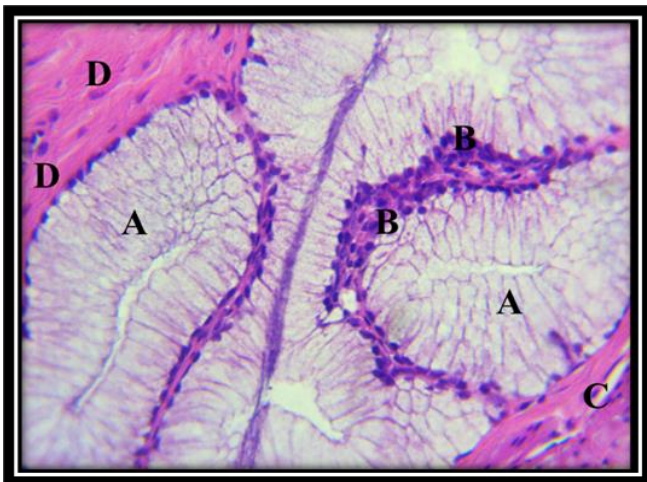

Fig. 2. Pharyngeal tissue - mucous pharyngeal glands with mucus droplets (A) infiltration of inflammatory white blood cells (B) at the bases of the cells of the glands primary lamina and containing colloidal fibers (C) smooth muscle layer (D). (H&E , 400X)

The crop showed that its folds contained disjointed epithelial cells consisting of several rows with a degeneration of a number of these cells in the spiny layer of the vesicle epithelium, and the basal layer contained more than a row of dark-colored cells and infiltration of some lymphocytes around them, as well as the infiltration of lymphocytes in The

main page of the disassembled colloidal fibers, which also contains some phagocytic cells, figure (3).

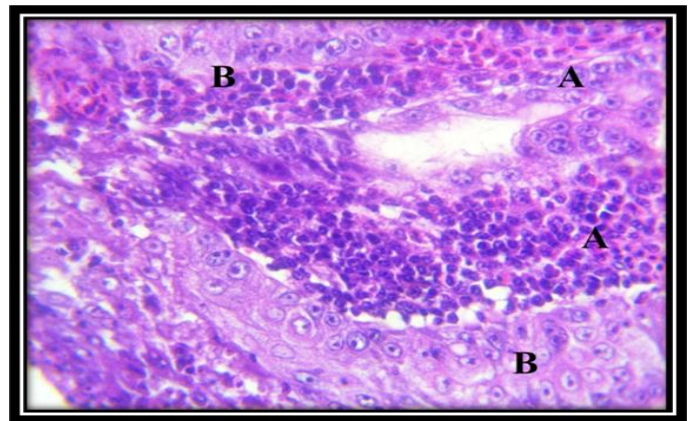


Fig. 3. Intrusion of large numbers of white blood cells (A) into the primary lamina of the vesicle, parasitic cysts (B). (H&E, 400X)

The interstitial tissue of the primary and submucosal lamina of the vesicle contained a massive infiltration of white blood cells surrounded by numerous parasitic sacs with eggs in which cells with prominent nuclei were also filled with cavities on some alveoli on parasite eggs as well as figure (4). The mucosal folds of the tongue surface in infected *G. gallus* contained degeneration of the outer rows of tongue epithelium and the deep rows of basal cells stacked together and composed of more than one row of dark-colored cells surrounded by connective tissue to the pulp of the folds and infiltrated white blood cells.

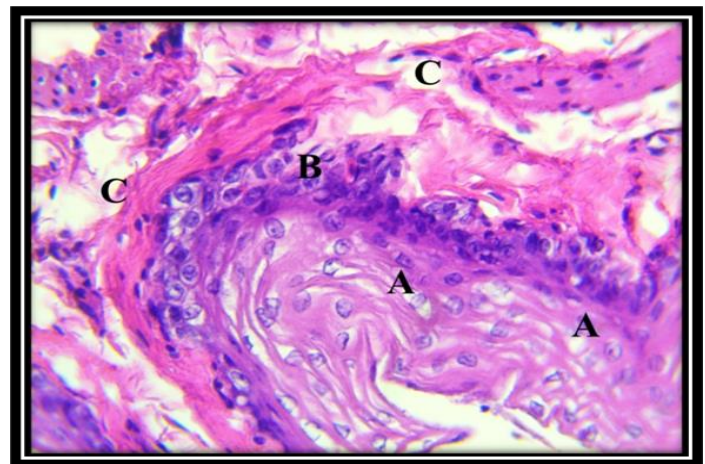


Fig. 4. The disassembled vesicle epithelium (A) with degeneration of its cells, the basal layer and infiltration of lymphocytes (B) lymphocytes in the disassembled primary lamina (C). (H&E , 400X)

As the pharynx epithelium was surrounded by dense fibrous connective tissue with infiltration of large numbers of white blood cells in a diffuse and nodular manner, and disintegration was found in bundles of colloidal fibers extending in the rest of the base plate (Fig. (6).

In the crop, it was noted that there were many necrosis of Ha cells and epithelial degenerations from the mucous folds of the crop of domesticated chickens. Most of these folds were damaged and were devoid of epithelial cells and surrounded the soft fibrous interstitial tissue containing infiltrated lymphocytes and parasitic cells (Fig. 7).

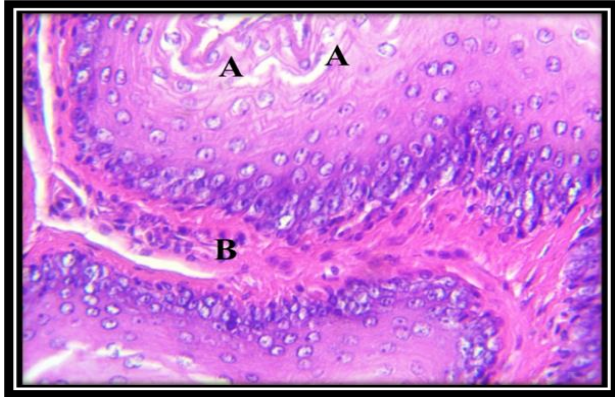


Fig. 5. The mucosal folds of the surface of the tongue with degeneration of the outer rows of the epithelium of the tongue (A) Infiltration of white blood cells (B) at the basal layer of the squamous epithelium (H&E ,400X)

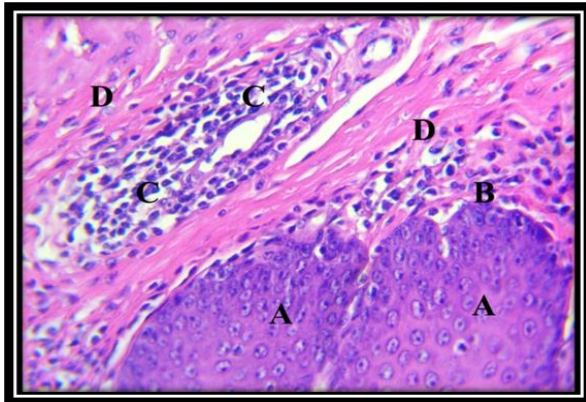


Fig. 6. squamous layered epithelium of the pharynx (A) diffuse (B) and nodular infiltration of lymphocytes (C) colloidal dense fibers in the primary lamina with fibroblasts (D) (C&E, 400X)

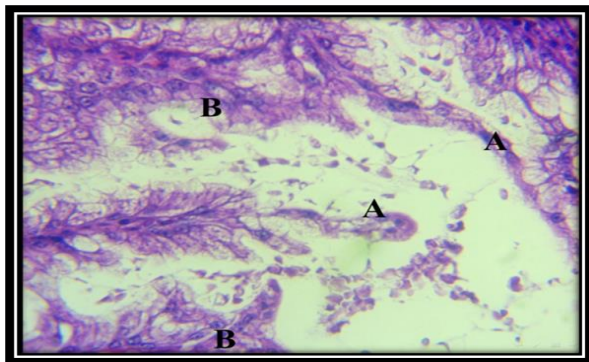


Fig. 7. Degeneration and degeneration of epithelial cells (A) in the mucous folds of the vesicle, infiltration of

lymphocytes (B) in the interstitial tissue, and parasitic cells (C). (H&E , 400X)

The tongue of *S. turtur* contained the lingual cartilage, in which severe necrosis appeared in most of its areas, and the presence of cell debris in the place of the necrotic ground substance (Figure 8).

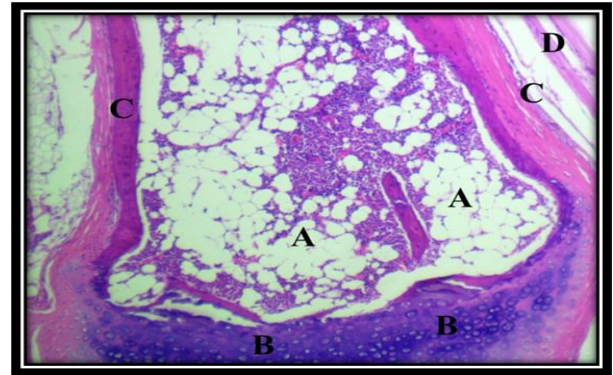


Fig.8. The tongue of the lunar pigeon has necrosis of most of the lingual cartilage and its cells are damaged (A) Normal cartilage cells (B) Periosteum (C) Skeletal muscle fibers (D) (H&E, 400X)

The epithelium of the pharynx, pharynx epithelium, contained sloughing of the surface cells and the presence of keratin threads sloughed off as well in the pharyngeal cavity. The basal cells were surrounded by numbers of scattered inflammatory white blood cells, some of which were found focally within the layer of the primary lamina (Picture 9). In the crop, many glands in the form of alveoli lined with epithelial cells were observed, with degeneration, with a cytoplasm containing gaps, and the interstitial tissue between glandular units filled with inflammatory white blood cells and macrophages, some of the gland cavities contained limited glandular secretions (Fig. 10).

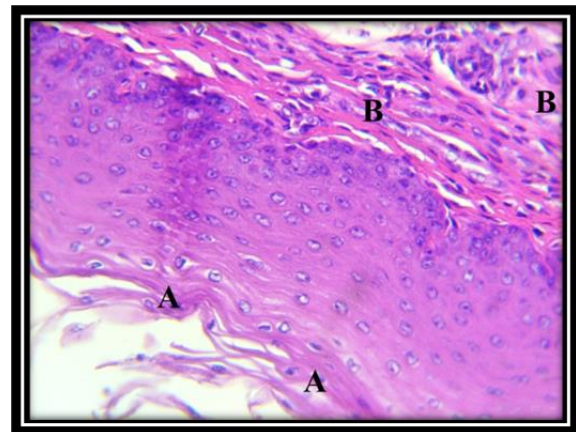


Fig. 9. Detachment of keratin filaments from the epithelial surface of the pharynx (A) Infiltration of white blood cells (B) in the base plate. (H&E ,400X)

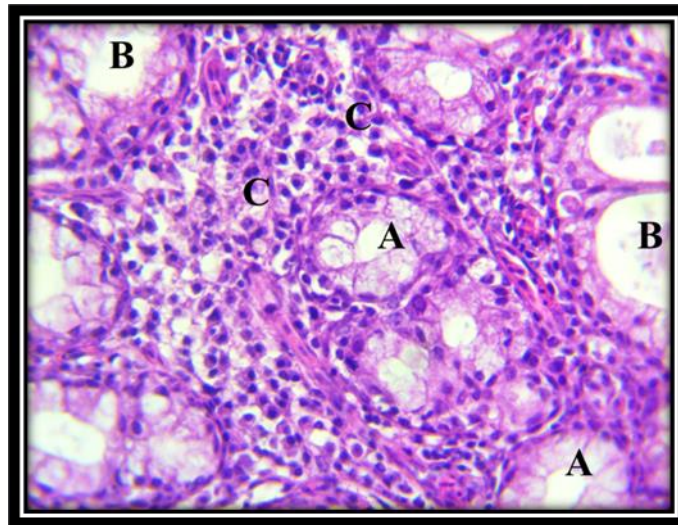


Fig. 10. Cyst of the lunar pigeon, degeneration of cells lining the glands (A) with loss of other cells (B) Massive infiltration of inflammatory white blood cells and macrophages (C) in the interstitial tissue)H&E ,400X

Table 1. Total infection rates with *T. gallinae* in birds under study

Birds type	Bird no. examined	Infected bird no.	%
<i>C. livia</i>	233	33	14.16
<i>G. gallus</i>	222	62	27.92
<i>S. turtur</i>	150	21	14.0
Total	605	116	19.17
		**	
		Chi-Square= 17.344 P-Value = 0.0007	

Table 2. Total infection rates with *T. gallinae* in birds under study by gender

Birds type	Bird no. examined	Gender					
		Female			Male		
		Bird no. examined	Infected no.	%	Bird no. examined	Infected no.	%
<i>C.livia</i>	233	115	14	%12.17	118	19	%16.10
<i>G.gallus</i>	222	132	34	%25.75	90	28	%31.11
<i>S.turtur</i>	150	57	7	%12.28	93	14	%15.05
total	605	260	49	%18.84	345	67	%19.42
		Chi-Square= 17.344 P-Value = 0.0007 **					

Table 3. Total infection rates with *T. gallinae* in birds under study by months

Monthes	<i>G. gallus</i>			<i>S. turtur</i>			<i>C. livia</i>		
	Bird no. examined	Infected no.	%	Bird no. examined	Infected no.	%	Bird no. examined	Infected no.	%
october	28	7	%25	21	2	%9	30	3	%1
november	43	9	%20	19	1	%5	41	5	% 12
december	51	12	%23	23	7	%30	50	9	%18
january	42	14	%33	25	8	%32	43	9	%20
february	33	11	%33	30	3	%1	26	4	%15
march	25	9	%36	32	0	لا يوجد	43	3	% 6
total	222	62	%27	150	21	%14	233	33	%14
Chi-Square=31.585 P-Value = 0.0009 **									

Conflict of Interest

The author hereby declares no conflict of interest.

Consent for publication

The author declares that the work has consent for publication

Ethical Considerations

The study was approved by the institutional ethical committee

Funding support

The author declares that they have no funding support for this study

References

Abd-El-Motelib, T. Y., & Galal, B. E. G. (1994). Some studies on *Trichomonas gallinae* infection in pigeons. *Assiut Veterinary Medical Journal*, 30(59), 277-288.

Al-Barwari, S., & Saeed, I. (2012). The parasitic communities of the rock pigeon *Columba livia* from Iraq: component and importance. *Türkiye Parazitoloji Dergisi*, 36(4), 232.

Alexander, J., & Stimson, W. H. (1988). Sex hormones and the course of parasitic infection. *Parasitology Today*, 4(7), 189-193.

Alrefaei, A. F., Gerhold, R. W., Nader, J. L., Bell, D. J., & Tyler, K. M. (2019). Improved subtyping affords better discrimination of *Trichomonas gallinae* strains and suggests hybrid lineages. *Infection, Genetics and Evolution*, 73, 234-241.

Al-Sadi, H. I., & Hamodi, A. Z. (2011). Prevalence and pathology of trichomoniasis in free-living urban pigeons in the city of Mosul, Iraq. *Veterinary World*, 4(1), 12.

Ning, T. Z., Kin, W. W., Mustafa, S., Ahmed, A., Noordin, R., Cheong, T. G., ... & Huat, L. B. (2012). Detection of *Entamoeba histolytica* in experimentally induced amoebic liver abscess: comparison of three staining methods. *Asian Pacific Journal of Tropical Biomedicine*, 2(1), 61-65.

Begum, N., Mamun, M. A. A., Rahman, S. A., & Bari, A. S. M. (2008). Epidemiology and pathology of *Trichomonas gallinae* in the common pigeon (*Columba livia*). *Journal of the Bangladesh Agricultural University*, 6(2), 301-306.

Brunthaler, R., Teufelbauer, N., Seaman, B., Nedorost, N., Bittermann, K., Matt, J., ... & Weissenböck, H. (2022). Trichomonosis in Austrian Songbirds—Geographic Distribution, Pathological Lesions and Genetic Characterization over Nine Years. *Animals*, 12(10), 1306.

Cover, A. J., Harmon, W. M., & Thomas, M. W. (1994). A new method for the diagnosis of *Trichomonas gallinae* infection by culture. *Journal of Wildlife Diseases*, 30(3), 457-459.

Dakheel Kremsh Alasadiy, Y., Mukdad Mahmood, R., & Naji Alhasnawi, A. (2022). A Comparative Study of Parasitic Infections in Domestic and Wild Pigeons in Iraq. *Archives of Razi Institute*, 77(2), 709-715.

Fadhil, L. T., & Faraj, A. A. (2019). Survey of *Trichomonas gallinae* isolates in pigeons by microscopy and PCR. *Online Journal of Veterinary Research*, 23(4), 321-329.

Jaafar, E. H. (2014). Prevalence of some epidemiological study of *Trichomonas gallinae* in domestic pigeons in Baghdad. *Iraqi J. Vet. Med*, 38, 1-4.

Jawad, R. A., Al-Ali, F., Rashid, I. F., Al-Sabbagh, J. K., Sulbi, I. M., Noor, M. A., & Saber, W. A. (2020). Prevalence Comparative Study of Infection with *Trichomonas* spp in The Three Types of Birds at The Holy City of Kerbala. *Indian Journal of Forensic Medicine & Toxicology*, 14(3), 2655.

Sun, L., Zhang, L., Yu, J., Zhang, Y., Pang, X., Ma, C., ... & Qiu, S. (2020). Clinical efficacy and safety of anti-PD-1/PD-L1 inhibitors for the treatment of advanced or metastatic cancer: a systematic review and meta-analysis. *Scientific reports*, 10(1), 1-13.

McKeon, T., Dunsmore, J., & Raidal, S. R. (1997). *Trichomonas gallinae* in budgerigars and columbid birds in Perth, Western Australia. *Australian Veterinary Journal*, 75(9), 652-655.

Purple, K. E., Humm, J. M., Kirby, R. B., Saidak, C. G., & Gerhold, R. (2015). *Trichomonas gallinae* persistence in four water treatments. *Journal of Wildlife Diseases*, 51(3), 739-742.

Saleem, M. H., Khan, M. S., Chaudry, A. S., & Samad, H. A. (2008). Prevalence of trichomoniasis in domestic and wild pigeons and its effects on hematological parameters. *Pakistan Vet. J.*, 28(2), 89-91.

Shuber, Habib Wasil Kazem (2006). Parasitic worms in the gut of Nettarefin and Anascrecca birds. Master's thesis, College of Education, University of Al-Qadisiyah.

Wahhab, M. A., Abdulrahman, N. R., & Ali, S. A. K. (2017). A study of oropharyngeal parasites infection in doves and domestic pigeons in some villages of Garmian-Iraqi Kurdistan region. *Kurdistan Journal of Applied Research*, 2(1), 15-20.

How to cite this article

Abdulla, B. N., Zangana, A. J. M. and Mohamed, A.S. (2022). Spread of *Trichomonas gallinae* in species of birds in balad district with the effect of infection on histological picture. *Microbial Science Archives*, Vol. 2(4), 34-41. <https://doi.org/10.47587/MSA.2022.2401>

This work is licensed under a [Creative Commons Attribution 4.0 International License](https://creativecommons.org/licenses/by/4.0/)



Publisher's Note: MD International Publishing stays neutral with regard to jurisdictional claims in published maps and institutional affiliations.